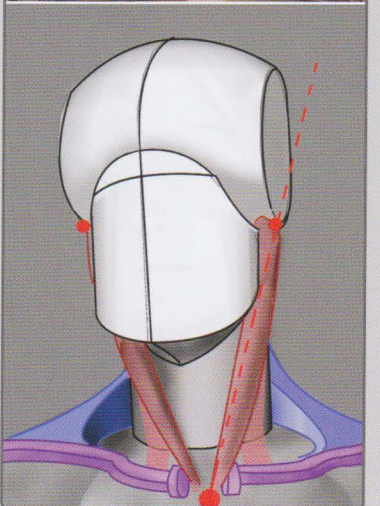
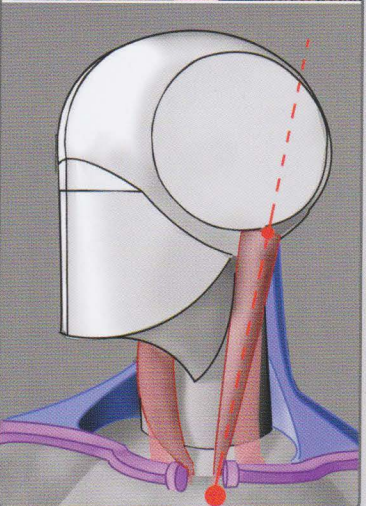
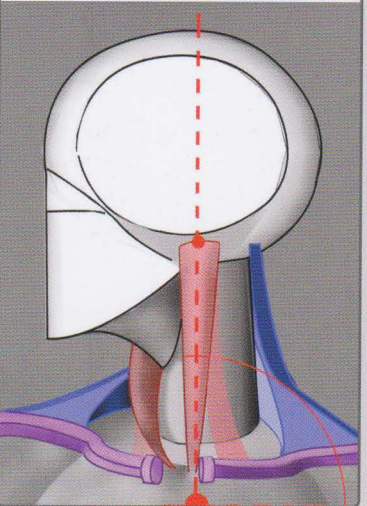
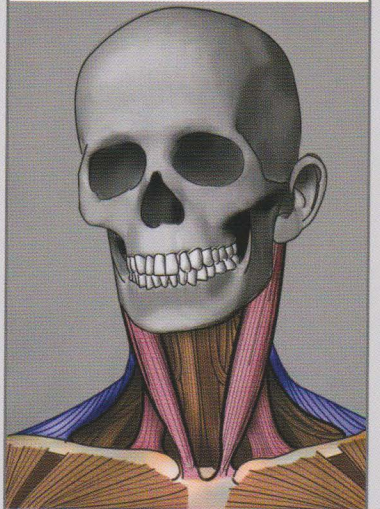
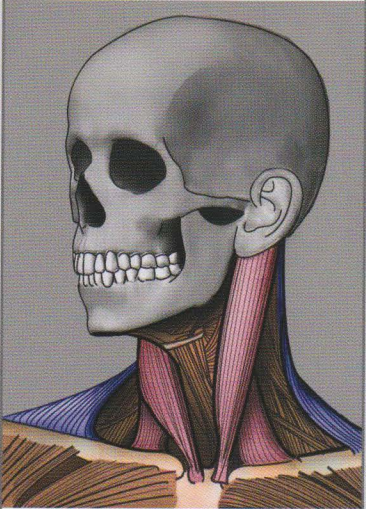
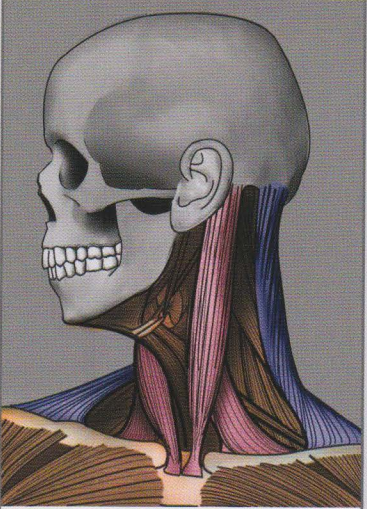

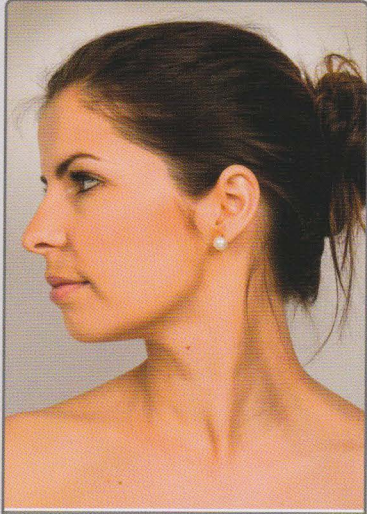
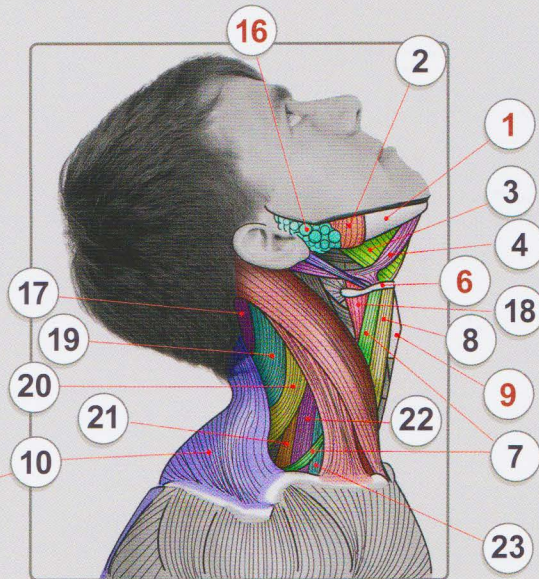
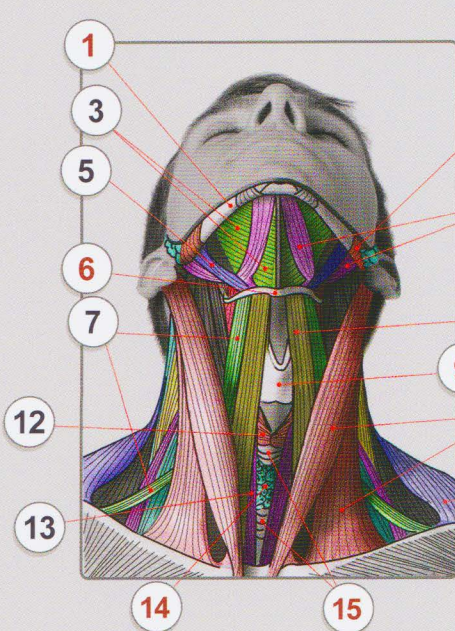
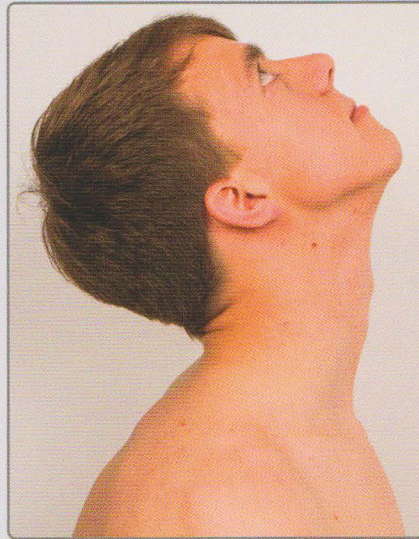
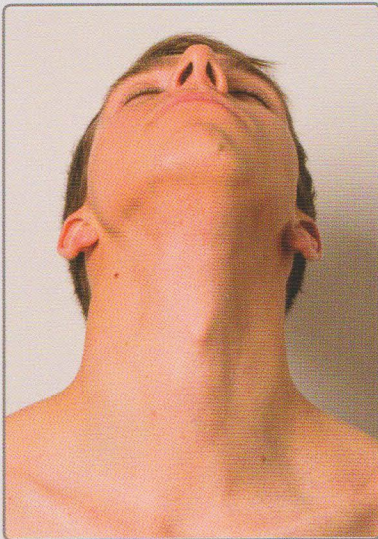


MAJOR NECK MUSCLES (TRAPEZIUS AND STERNOCLEIDOMASTOID)



MAIN NECK MUSCLES



- | | | |
|-------------------------------|--|--------------------------------|
| 1 LOWER JAW (MANDIBLE) | 9 ADAM'S APPLE (LARYNGEAL PROMINENCE) | 17 SEMISPINALIS CAPITIS |
| 2 MASSETER | 10 TRAPEZIUS | 18 HYOGLOSSUS |
| 3 MYLOHYOID | 11 STERNOCLEIDOMASTOID | 19 SPLENIUS CAPITIS |
| 4 DIGASTRIC | 12 CRICOTHYROID | 20 LEVATOR SCAPULAE |
| 5 STYLOHYOID | 13 STERNOTHYROID | 21 SCALENUS POSTERIOR |
| 6 HYOID BONE | 14 THYROID GLAND | 22 SCALENUS MEDIUS |
| 7 OMOHYOID | 15 TRACHEA | 23 SCALENUS ANTERIOR |
| 8 STERNOHYOID | 16 PAROTID GLAND | |