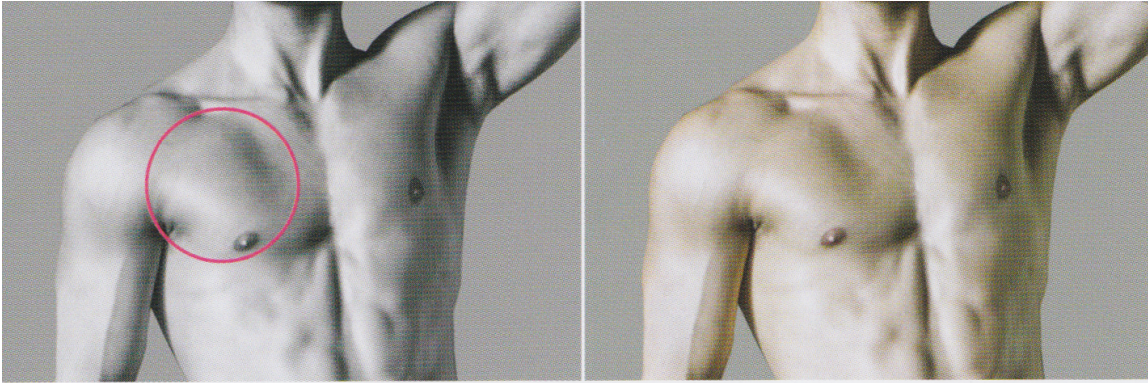
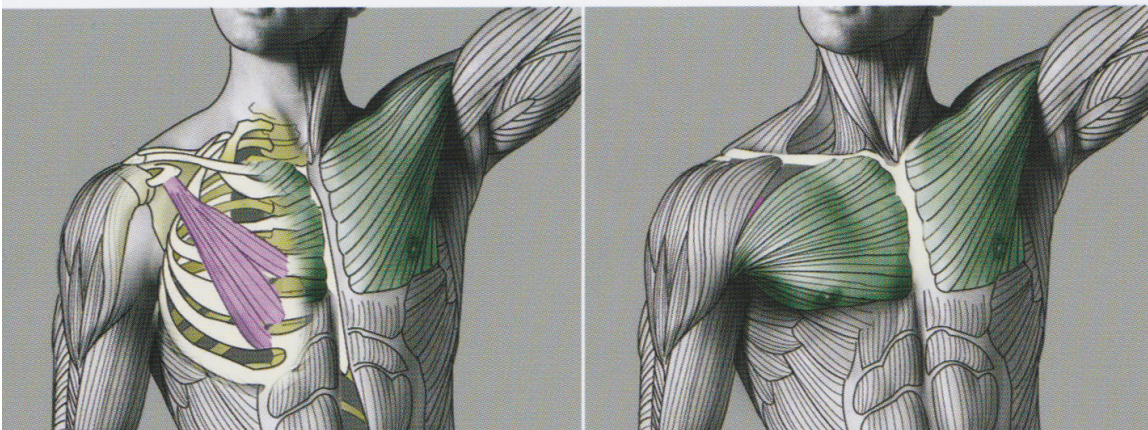


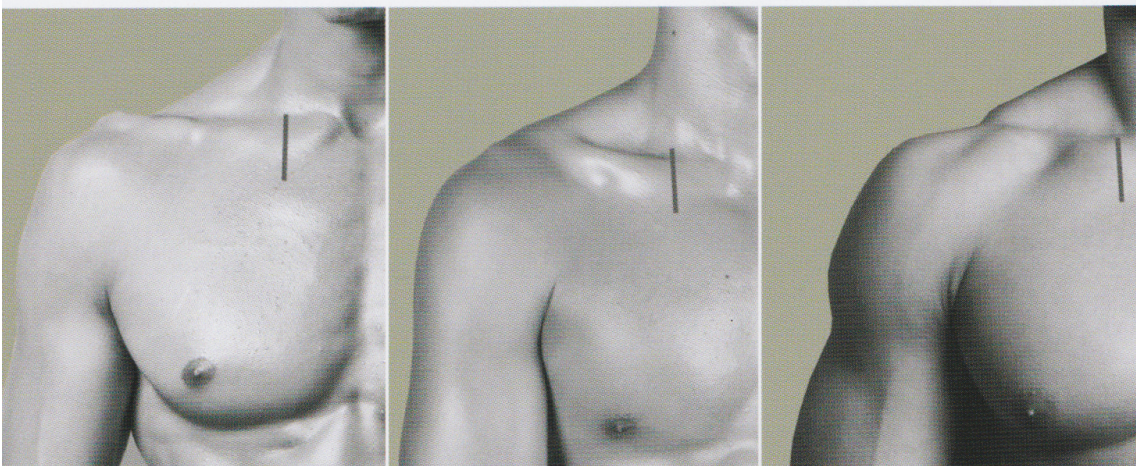
What is this bulge?



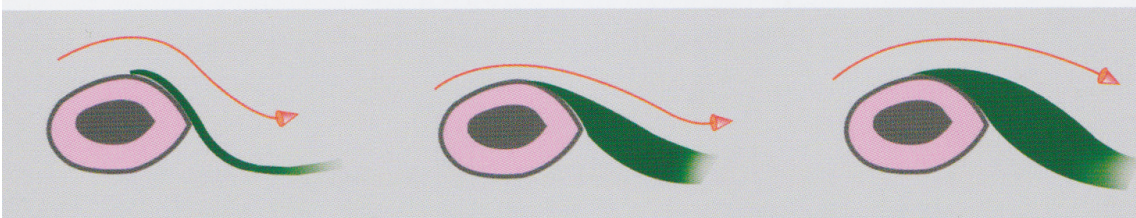
THE **PECTORALIS MINOR** MUSCLE PUSHES THE **PECTORALIS MAJOR** OUTWARD FROM UNDERNEATH.



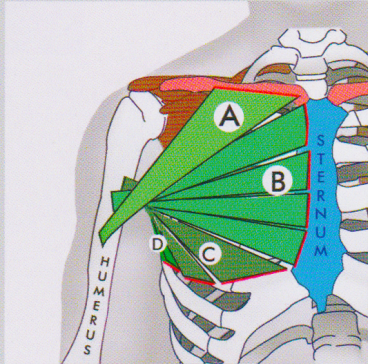
AS **CHEST MUSCLES** BECOME MORE DEVELOPED, LESS **COLLAR BONE (CLAVICLE)** IS VISIBLE.



CROSS SECTION OF **COLLAR BONE (CLAVICLE)** AND **CHEST MUSCLE (PECTORALIS MAJOR)**.



Pectoralis Major

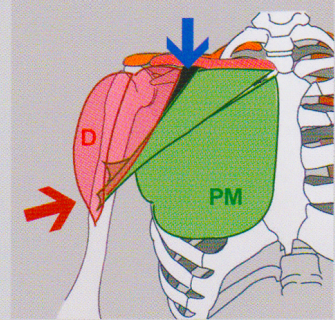


ONE END OF THE PECTORAL MUSCLE (PM) IS CONNECTED TO THE HUMERUS AND OTHER END CONNECTS:

- A: TO 3/5 OF THE **CLAVICLE**
- B: TO THE **STERNUM**
- C: TO THE **RIBS**
- D: TO APONEUROSES OF THE ABDOMINAL OBLIQUE MUSCLES

A: THIS PORTION IS OFTEN VISIBLE AS A SEPARATE PART OF THE PM.

HOLLOW AREA BETWEEN THE PM AND THE DELTOID (D) IS ALWAYS VISIBLE!



PM IS PARTIALLY COVERED BY THE DELTOID (D) MUSCLE.

